



Research Article

Effect of sesamol in association with folic acid on 6-OHDA induced parkinsonian animals- Biochemical, Neurochemical and Histopathological evidence

Khadira SA¹, Vijayalakshmi K², Nagappan P¹, Balima S³

¹Department of Biochemistry, Bharathi Women's College, Chennai, Tamil Nadu, India, ²Department of Biochemistry, Bharathi Women's College, Chennai, Tamil Nadu, India, ³Microtherapeutics Research lab pvt. Ltd, Padi, Chennai, Tamil Nadu, India

Address for Correspondence
Vijayalakshmi K
E-mail : viji42research@yahoo.co.in

Received : 07-06-2015
Review completed: 04-08-2015
Accepted : 11-08-2015

ABSTRACT

Parkinson's disease (PD) is the world's second important neurodegenerative disorder. Degeneration of dopaminergic neurons is the hallmark of the disease. Here is a novel approach to treat PD with a phenolic compound sesamol (SA) and Folic acid (FA). The study was designed with five groups of animals and 6 rats in each group. The rats was infused with 6-hydroxydopamine (10µg/2µl in 0.1% ascorbic acid) once for the development of PD, Group 1(control), Group 2(Lesion), Group 3(Lesion+ SA), Group 4(Lesion + SA+ FA) and Group 5(Lesion+ L-dopa). The biochemical parameter like glucose, triglycerides, protein, folic acid, TBARS and antioxidant profile in serum were estimated. The neurotransmitters level in striatum was estimated and histopathology of striatal tissue was carried out. The results showed that 6-hydroxydopamine induced lesion has a significant alteration in the level of glucose, triglycerides, protein and folic acid where as TBARS level was elevated and the activities of antioxidant and neurotransmitters level were reduced. This was significantly restored on SA+FA treatment. The lesion group shows an abnormal architecture of striatum and on SA+FA treatment the abnormalities was normalised and show clear architecture. Thus our study demonstrates that Sesamol has neuroprotective effect against 6-hydroxy dopamine insult and show a synergic effect when combined with Folic acid.

Key words:

Parkinson's disease, Sesamol, Folic acid, 6-Hydroxy dopamine, Neurotransmitter, Antioxidant apoptosis.

INTRODUCTION

Neurodegenerative disorders are common among elderly people. Parkinson's disease (PD) is the world's second neurodegenerative disorder next to Alzheimer's disease. The degeneration of dopaminergic neurons of substantia nigra pars compacta is the pathology of the disease. This kind of degeneration will reduce the level of neurotransmitter called dopamine, which is involved in the locomotory event of the body. The dopamine depletion causes disregulation in motor circuit of basal ganglia¹. This leads to motor impairment like bradykinesia, muscular rigidity, tremor and postural instability. The degeneration may be due to oxidative stress, iron deposition, environmental toxins, mitochondrial dysfunction and

protein aggregation (lewy body)². The current medical strategy is just to alleviate the symptoms of the disease with L-dopa administration. Though L- dopa was found to be gold standard for the past 40 years it causes side effects like sleep disturbance and emotional problems. Oxidative stress is the basic precursor for almost all the deadly diseases. PD is also one among them³. Thus it has been focused to find natural antioxidants like curcumin, epigallocatechin-3-gallate, melatonin, etc⁴. On this path we have chosen the most powerful antioxidant sesamol present in sesame seeds. Sesamol (SA) is a natural organic compound present in sesame oil extracted from *Sesamum indicum* that belongs to Pedaliaceae family. Numerous wild relative species are found in Africa and a smaller number in India. SA has various activities like antioxidant, antifungal, neuroprotective⁵, photoprotective⁶ and

Access this article online	
QR Code	Website: www.ijrpsonline.com
	

hepatoprotective⁷. Along with sesamol, folic acid (FA) was combined, as FA is involved in the synthesis of dopamine and it is to be noted that FA deficiency causes PD⁸. Therefore the present study was planned to evaluate the effect of SA in association with FA on 6-hydroxy dopamine (6-OHDA) induced Parkinsonian animals in comparison with L-dopa. The general blood parameters like glucose, triglycerides, protein and folic acid was estimated. The activities of Superoxide dismutase, Catalase, Glutathione peroxidase and Glutathione reductase, and the levels of Glutathione, Vitamin-C, Vitamin- E and TBARS in serum of experimental animals were estimated. The levels of neurotransmitter like Dopamine (DA), nor-epinephrine (NE), homovanillic acid (HVA) and 3,4-dihydroxy phenyl acetic acid (DOPAC) in striatum of animals was measured by fluorimetric analysis. The tissue morphology of striatal tissue was studied by histopathology.

MATERIALS AND METHODS

Chemicals:

6-Hydroxydopamine, Sesamol (SA), L-Dopa, Apomorphine, Folic acid (FA) and ascorbic acid were purchased from Sigma-Aldrich. All the other chemicals used for the study were of analytical grade.

Experimental protocol:

Male Wistar rats of weight 200–250 g were purchased and maintained at 25±2°C in 12 h light/dark cycle with free access to food and water. The animal protocol was approved by the Institutional Animal Ethical Committee of Saveetha University (SU/BRULAC/RD/004/2013). The rats were segregated into five groups, 6 rats in each group, Group 1(control), Group 2(Lesion), Group 3(Lesion+ SA), Group 4(Lesion + SA+ FA) and Group 5(Lesion+ L-dopa). The rats were anesthetized and infused with 6-hydroxydopamine at the rate of 1µl/min, 2µl of 6-hydroxydopamine (10µg/2µl in 0.1% ascorbic acid) was injected intrastrially in right striatum once for the development of PD. The regions were located according to rat brain atlas (antero-posterior 0.5 mm, lateral 2.5 mm, dorso-ventral 4.5mm relative to bregma and ventral from dura). After 21 days the disease development was confirmed by Apomorphin induced contra lateral rotational test⁹. The animals were treated with SA (30mg/kg body weight, intra peritoneally), FA (5mg/kg body weight, orally) and L-dopa (100mg/kg, orally) for the next 24 days.

Sample collection:

After the experimental period (45days) animals were sacrificed by cervical dislocation. Anaesthesia was not given as it alters the brain amines¹⁰. Blood was collected by cardiac puncher. The brains are removed immediately striatum was dissected and processed for neurochemical and histopathological study.

Biochemical parameters:

i) Estimation of blood glucose:

The blood glucose level was estimated by glucose oxidase method¹¹.

ii) Estimation of protein:

The protein was estimated by Lowry method¹².

iii) Estimation of Triglycerides:

Triglyceride levels of experimental animals are estimated by method of Rice¹³.

iv) Estimation of folic acid:

Folic acid in serum of experimental animals was estimated by simple spectrophotometric method of Nagaraja et al.,¹⁴

Estimation of Antioxidant profile in serum of animals:

Enzymatic antioxidants, such as Superoxide dismutase¹⁵, Catalase¹⁶, Glutathione Peroxidase¹⁷ and Glutathione Reductase¹⁸ and non-enzymatic antioxidant like Glutathione (GSH)¹⁹, Vitamin-C²⁰ and Vitamin- E²¹. Level of TBARS was also estimated as specified by Ohkawa et al.,²².

Estimation of Neurotransmitter levels in Striatum of animals:

i) Dopamine and Nor-epinephrine estimation:

The striatum was homogenized with acidified butanol and centrifuged at 800g. Aliquots served as test samples. DA and NE were estimated by the method of Kari et al.,²³ with slight modification. The internal standard was prepared by known amount DA (1µg) and NE (1µg). The fluorescence of DA and NA was read at (320nm and 370nm) and (385nm and 485nm) respectively, with a slit width of 10/10nm.

ii) HVA and DOPAC estimation:

The homogenized striatal tissue sample was extracted with Tris for HVA estimation and 1, 2-diaminoethen for DOPAC estimation according to method of Murphy et al.,²⁴. The fluorescence of HVA was measured at 315nm and 430nm and DOPAC was measured at 385nm and 450nm, with 5mm width slit.

Histopathological study:

The striatal tissue was dissected from each group of animals. The tissues were fixed in 10% formalin and processed. The fixed tissues were embedded in paraffin wax and sectioned on gelatine coated glass slide. The sections were stained with haemotoxylin and eosin then observed under light microscope. Brain striatal sections were examined for pathological changes and compared with control group.

Statistical analysis:

The results are expressed as Mean ±S.E.M. Oneway-Analysis of variance was applied on the data to derive the significance of the results. The *p* value < 0.001 was considered statistically significance.

RESULTS AND DISCUSSION

Biochemical Parameters:

Estimation of glucose, triglycerides and protein (Table 1) shows that there is a significant variation (P<0.001) between control animals (Group1) and lesion animals (Group 2) and this was restored by SA+FA treatment. In comparison with lesion animals SA+FA treated animals showed significant increase than SA treated animals and L-dopa animals. The folic acid level shown in Table 1 indicates that all the groups has folic acid level was within the normal range 5-16ng/mL. But there is a significant difference between control animals and lesion animals. The SA+FA treated animals shows normal level of folic acid which was significant P<0.001 when compared with Lesion animals.

Table 1: Biochemical Parameters of experimental animals in serum

Parameters	Group 1 (control)	Group 2 (Lesion)	Group 3 (Lesion+SA)	Group 4 (Lesion+SA+FA)	Group 5 (Lesion+L-Dopa)
Glucose (mg/dl)	111.89±2.53	96.54±2.07*	98.87±1.07 ^{NS}	107.74±1.26 [#]	96.34±0.43 ^{NS}
Protein (g/dl)	6.34±0.02	6.05±0.01*	6.24±0.01 [#]	6.36±0.01 [#]	6.23±0.02 [#]
Triglycerides (mg/dl)	74.46±0.48	62.55±0.64*	68.29±1.06 [#]	71.09±0.63 [#]	64.30±0.51 ^{NS}
Folic Acid (ng/mL)	12.85±0.46	10.25±0.15*	10.92±0.17 ^{NS}	14.65±0.14 [#]	10.85±0.23 ^{NS}

The value are expressed in mean ±S.E.M, * = p value <0.001 comparison between Group 1 & Group 2. # = p<0.001, NS – non-significant comparison between Group 2 and Group 3, Group 4 & Group 5.

Enzymatic Antioxidant activity in Serum of experimental animals:

Table 2. indicates the enzymatic antioxidant activities of Superoxide dismutase, Catalase, Glutathione reductase and Glutathione peroxidase. There was a significant decrease in the activity of these enzymes in the lesion group animals when compared with control group animals. But on treatment with SA, FA and L-dopa the enzyme activity has increased. Among Group 3, Group 4 and Group 5 animals Group 4 animal shows significant (P<0.001) increase in the activity when compared with Group 2 animals.

Table 2: Enzymatic Antioxidant activity in Serum of experimental animals

Enzymes	Group 1 (control)	Group 2 (Lesion)	Group 3 (Lesion+SA)	Group 4 (Lesion+SA+FA)	Group 5 (Lesion+L-Dopa)
SOD U/mg protein	5.41±0.06	3.14±0.13*	3.69±0.06 [#]	4.75±0.10 [#]	3.41±0.06 ^{##}
Catalase (31.96±	21.37±0	24.34±0.	30.29±1.	22.36±0.

µmol H ₂ O ₂ consumed/m in/mg Protein)	0.50	.24*	32 ^{##}	90 [#]	33 ^{NS}
GPx (µmol NADPH oxidize/min/mg Protein)	3.65±0.04	1.97±0.09*	2.38±0.14 [#]	3.20±0.07 [#]	2.94±0.05 [#]
GRx (µmol NADPH oxidize/min/mg Protein)	2.90±0.08	1.51±0.03*	1.81±0.04 ^{##}	2.52±0.05 [#]	2.10±0.04 [#]

The value are expressed in mean ±S.E.M, * = p<0.001 comparison between Group 1 and Group 2. # = p<0.001, ## = p<0.01, NS – non-significant are comparison between Group 2 and Group 3, Group 4 & Group 5.

Non-Enzymatic Antioxidant and TBARS levels in Serum of experimental animals:

The levels of antioxidant such as Glutathione (GSH), Vitamin-C and Vitamin-E of experimental animals were shown in Table 3. It was found that the antioxidant levels were significantly decreased in Lesion group animals when compared with Control animals. This was restored by treatment. In comparison with Lesion group, Group 3, Group 4 and Group 5 animals shows significant increase (P<0.001) in levels. Group 4 animals show near normal level, that is the SA+FA treated animals shows better effect than other group. On other hand the TBARS of Lesion group animals was significantly increased when compared with control group. This was reduced significantly in Group 3, Group 4 and Group 5 in comparison with Lesion group. Group 4 animals (SA+FA treated) show better result than other groups.

Table 3: Non-Enzymatic Antioxidant and TBARS levels in Serum of experimental animals

Antioxidant	Group 1 (control)	Group 2 (Lesion)	Group 3 (Lesion+SA)	Group 4 (Lesion+SA+FA)	Group 5 (Lesion+L-Dopa)
GSH (µg/mg protein)	4.80±0.13	2.49±0.16*	3.31±0.07 [#]	4.67±0.04 [#]	3.55±0.06 [#]
Vitamin-C(mg/dl)	1.73±0.03	0.98±0.03*	1.25±0.03 [#]	1.69±0.02 [#]	1.46±0.02 [#]
Vitamin-E (mg/dl)	1.84±0.03	1.02±0.03*	1.21±0.02 [#]	1.66±0.02 [#]	1.36±0.03 [#]
TBARS (nmol/ml)	3.94±0.11	7.16±0.18*	5.99±0.08 [#]	4.53±0.15 [#]	6.21±0.06 [#]

The value are expressed in mean ±S.E.M, * = p<0.001 comparison between Group 1 and Group 2. # = p<0.001, NS – non-significant are comparison between Group 2 and Group 3, Group 4 & Group 5.

Neurotransmitter levels in striatum of experimental animals:

Figure 1. shows the levels of Dopamine, Nor-epinephrine, DOPAC and HVA. It indicates the levels of neurotransmitter in striatum of animals in Lesion group were significantly (p < 0.001) reduced from levels of neurotransmitter of control group animals. On SA, FA, and

L-dopa treatment the levels was increased. Among treatment groups the SA+FA treated group shows increased level of neurotransmitter which was highly significant ($p < 0.001$) in comparison with Lesion group.

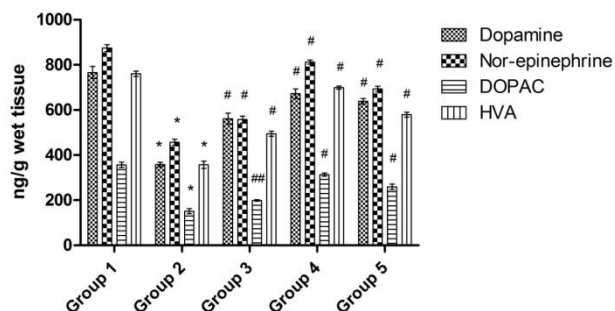


Figure 1: Neurotransmitter levels in Striatum of experimental animals. Group 1- Control, Group 2-Lesion with 6-OHDA, Group 3- Lesion +SA, Group 4- Lesion +SA+FA, Group 5- Lesion +L-dopa. The values are expressed in Mean \pm SEM. p value < 0.001 was expresses as *comparison between Control group and Lesion group, whereas # - p value < 0.001 and ## - p value <0.01 comparison between Lesion group and Group 3, Group 4 & Group 5.

Histopathological evidence of Striatum of experimental animals:

Figure 2 A-E shows the histopathology of the striatum of experimental animals. The control animal (A) shows normal architecture of striatal tissue, whereas on 6-OHDA insult the changes such as cellular inflammation, vascular degeneration and cytoplasmic vacuolation are visualised in lesion group animals (B). There was improvement on SA treated group (C) and SA+ FA treated group (D), but there is no improvement in L-dopa treated group (E). Among SA treated group and SA+FA treated group, the latter group shows better architecture of striatum similar to control group.

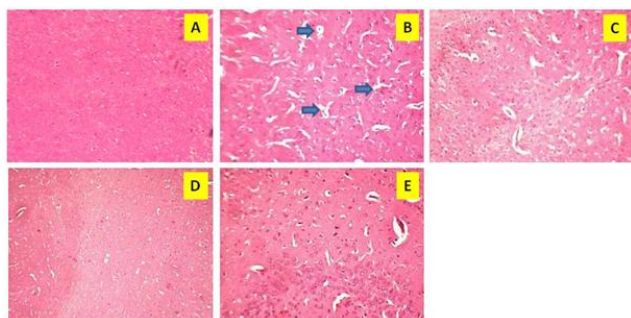


Figure 2 A-E: Histopathology of experimental Animals (Striatum). A - Control group, B - Lesion group, C - Lesion +SA treated group, D - Lesion +SA+FA treated group and E - Lesion +L-dopa treated group.

DISCUSSION

Our study demonstrates that the intrastriatal administration of 6-OHDA reduces the striatal neurotransmitters level, antioxidant activity in serum and shows abnormal architecture of striatal tissue. This kind of effect proves that the 6-OHDA toxication is the ideal animal model for PD studies^{25,26}. The levels of glucose, triglycerides and protein were estimated and we found significant alteration between the control, lesion and treated group. The study by Maryam Khombi Shooshtari et al., shows that the FA

supplement has improved memory and motor activity of adult rats²⁷. This supports our finding, as the SA+FA treated animals show normal level of folic acid in serum. In our previous study we have executed the behavioural activity and antioxidant profile in rats brain induced with 6-OHDA and found that SA+FA treated group animals showed improved behavioural activity and antioxidant profile²⁸. The oxidative stress was found to be one of the main culprit for PD. Thus it is important to evaluate the antioxidant profile of animals. In this study the serum antioxidants were measured and we found that the enzymatic antioxidant activities (superoxide dismutase, catalase, glutathione reductase and glutathione peroxidase) and levels of glutathione (GSH), Vitamin C and Vitamin E was reduced in the case of lesion group and it was restored by SA and FA treatment. On other hand the 6-OHDA induction increases the TBARS level in serum and our study was supported by other studies^{29,30}. The increased level of TBARS was reduced upon SA+FA treatment. The neurotransmitter levels in striatum of animals were depleted on 6-OHDA toxication which was restored on SA, FA and L-dopa treatment. The histopathological evidence shows that morphological changes like cellular inflammation, vascular degeneration and cytoplasmic vacuolation induced by 6-OHDA was restored on SA+FA treatment. SA+FA has a protective effect on striatal neurons and show a clear texture of striatal tissue as similar to control group. On other hand the L-dopa could only alleviate the symptoms and it does not prevent degeneration or protect the neurons. With these results we emphasise that sesamol in association with folic acid shows better neuroprotective effect in treating Parkinsonian animals induced with 6-OHDA and it might serve as a novel therapeutic drug. Further investigations and clinical trials are required to justify the same.

REFERENCES

1. Wood-Kaczmar A, Gandhi S, & Wood N W. Understanding the molecular causes of Parkinson's disease. Trends in molecular medicine. 2006; 12(11): 521-528.
2. Dauer William, and Serge Przedborski. Parkinson's disease: mechanisms and models. Neuron. 2003; 39(6):889-909.
3. Gatto E M, Carreras M C, Pargament G A, Riobo N A, Reides C, Repetto M & Poderoso J. J. Neutrophil function, nitric oxide, and blood oxidative stress in Parkinson's disease. Movement disorders. 1996; 11(3): 261-267.
4. Seidl S E & Potashkin J A. The promise of neuroprotective agents in Parkinson's disease. Frontiers in neurology. 2011; 2(68): 1-19.
5. Narasimhan Rangarajan, Muthukumar Vaithyanathan, and Vanisree Janardanam. Neuroprotective effect of sesamol in glioma induced in rats. Biomedicine International. 2011; 2: 22-27.
6. Prasad NR, Mahesh T, Menon VP, Jeevanram RK, Pugal-endi KV. Photoprotective effect of sesamol on UVB-radiation induced oxidative stress in human

- blood lym-phocytes in vitro. *Environ Toxicol Pharmacol.* 2005; 20(1):1-5.
7. Chandrasekaran V R M, Hsu D Z, & Liu M Y. The protective effect of sesamol against mitochondrial oxidative stress and hepatic injury in acetaminophen-overdosed rats. *Shock.* 2009; 32(1): 89-93.
 8. Duan W, Ladenheim B, Cutler RG et al., Dietary folate deficiency and elevated homocysteine levels endanger dopaminergic neurons in models of Parkinson's disease. *Journal of neurochemistry.* 2002; 80(1): 101-110.
 9. Ziegler Marilyne GM, and Henry Szechtman. Relation between motor asymmetry and direction of rotational behaviour under amphetamine and apomorphine in rats with unilateral degeneration of the nigrostriatal dopamine system. *Behavioural brain research.* 1990; 39(2):123-133.
 10. Ravindran R, Sheela Devi R, Samson J, Senthilvelan M. Noise stress induced brain neurotransmitter changes and the effect of *Ocimum sanctum* Linn treatment in albino rats. *Jap Phamacol Sci.* 2005; 98: 354-360.
 11. Triender P. Determination of glucose using glucose oxidase with an alternative oxygen acceptor, *Annu. Clin. Biochem.* 1969; 6 : 24–27.
 12. Lowry OH, Rosebrough NJ, Farral, Randall RJ. Protein measurement with the Folin phenol reagent. *J Biol Chem.* 1951; 193(1): 265- 75.
 13. Rice EW. Triglycerides (“neutral fats”) in serum. In *Standard Methods of Clinical Chemistry.* 1970; 6: 215–22.
 14. Nagaraja P, Vasantha R & Yathirajan HS. Spectrophotometric determination of folic acid in pharmaceutical preparation by coupling reaction with iminodibenzyl or 3-aminophenol or sodium molybdate – pyrocatechol. *Anal Biochemistry.* 2002; 307(2): 316-21.
 15. Marklund Stefan and Gudrun Marklund. Involvement of the superoxide anion radical in the autoxidation of pyrogallol and a convenient assay for superoxide dismutase. *European Journal of Biochemistry.* 1974; 47(3): 469-474.
 16. Sinha Asru K. Colorimetric assay of catalase. *Analytical biochemistry.* 1972; 47(2): 389-394.
 17. Rotruck JT, Pope AL, Ganthes HF, Swanson AB, Hafeman DG and Hoekstra WG. Selenium biochemical role as a component of Glutathione Peroxidase. *Science.* 1973; 179(73): 588-590.
 18. Mohandas J, Marshall JJ, Duggin GG, Horvath JS, Tiller D. Differential distribution of glutathione and glutathione related enzymes in rabbit kidneys: possible implication in analgesic neuropathy. *Cancer Res.* 1984; 44: 5086–5091.
 19. Moron MS, DePierre JW and Manerwik KB. Levels of glutathione, glutathione reductase and glutathione –S-Transferase in rat lung and liver. *Biochemica Biophysica Act.* 1979; 582: 67-68.
 20. Omaye ST, Turnbull JD, Sauberlich HE. Selected methods for the determination of ascorbic acid in animal cells, tissues and fluids. In: McCormick DB, Wright LD, editors. *Methods in enzymology.* New York: Academic Press. 1979; 62: 3 -11.
 22. Indrajeet D Desai. Vitamin E analysis methods for animal tissues, *Methods in enzymology.* 1984; 105:138 - 147.
 23. Ohkawa H, Ohishi N, Yagi K. Assay for lipid peroxides in animal tissues by thiobarbituric acid reaction. *Anal. Biochem.* 1979; 95: 351-358.
 24. Kari HP, Davidson PP, Herbert HH, Kochbar MH: Effects of ketamine on brain monoamine levels in rats. *Res Comm Chem Path Pharmacol.* 1978; 20: 475-488.
 25. Murphy GF, D Robinson and DF Sharman. The effect of tropolone on the formation of 3,4-dihydroxyphenylacetic acid and 4-hydroxy-3-methoxyphenylacetic acid in the brain of the mouse. *Br. J. Pharmac.* 1969; 36: 107-115.
 26. Alain Courtie` re, Jeannine Hardouin, Virginie Locatelli, Nathalie Turle-Lorenzo, Marianne Amalric, Franck Vidal and Thierry Hasbroucq. Selective effects of partial striatal 6-OHDA lesions on information processing in the rat. *European Journal of Neuroscience.* 2005; 21: 1973–1983.
 27. Nicola Simola, Micaela Morelli and Anna R Carta. The 6-Hydroxydopamine Model of Parkinson's Disease. *Neurotoxicity Research.* 2007; 11(3, 4): 151-167.
 28. Maryam Khombi Shooshtari, Ahmad Ali Moazedi, Gholam Ali Parham. Memory and Motor Coordination Improvement by Folic Acid Supplementation in Healthy Adult Male Rats. *Iranian Journal of Basic Medical Sciences.* 2012; 15 (6): 1173-1179.
 29. A.Khadira sreen, Priya Nagappa, Vijayalakshmi K. Effect of sesamol and folic acid on behavioural activity and antioxidant profile of rats induced with 6-hydroxy dopamine *International journal of pharmacognosy and phytochemical research.* 2015; 6(4): 930-93.
 30. Khuwaja G, Khan M M, Ishrat T, Ahmad A, Raza S S, Ashafaq M & Islam F. Neuroprotective effects of curcumin on 6-hydroxydopamine-induced Parkinsonism in rats: behavioral, neurochemical and immunohistochemical studies. *Brain research.* 2011; 1368: 254-263.
 31. Roy A, Ghosh A, Jana A, et al., Sodium phenylbutyrate controls neuroinflammatory and antioxidant activities and protects dopaminergic neurons in mouse models of Parkinson's disease. *PloS one.* 2012; 7(6): e38113.