

Craniotomy: A Novel Tool for Removal of Brain Tumor

Khan Ayesha Tazeen , Nikalje Anna Pratima*

Department of Pharmaceutical Chemistry, Y. B. Chavan College of Pharmacy
Dr. Rafiq Zakaria Campus, Rauza Bagh, Aurangabad. 431001. MS. India

ABSTRACT:

Brain surgery has undergone major developments over the past 15 years or so. A craniotomy is a type of brain surgery. A neurosurgeon performs a craniotomy to open the skull and remove the tumor. Surgery is the primary treatment for brain tumors that can be removed without causing very severe damage. So many benign (non-cancerous) tumors are treated only by surgery. Many malignant (cancerous) tumors require treatment along with surgery, such as radiation therapy or chemotherapy. The primary goal of brain tumour surgery usually is to remove as much of the tumour as possible without injury to the surrounding areas of brain. This might be complicated if the boundaries of the tumour cannot be identified easily at surgery, or if tumour is invading critical structures like blood vessels or cranial nerves. The purpose of writing this review on craniotomy was to compile the focus on preventing future problems or deterioration from tumour growth or hemorrhage. Curing the condition (benign tumours).Increasing the length and quality of survival time (malignant tumours).craniotomy opens new challenges and opportunities for the development of novel improved surgical therapies.

KEYWORDS: Tumor, Craniotomy, Anesthetics, anticonvulsant

***Corresponding Author:**

Dr. Anna Pratima Nikalje, Prof. & Head,
Dept. of Pharmaceutical Chemistry
Y. B. Chavan College of Pharmacy, Dr. Rafiq Zakaria Campus,
Rauza Bagh, Aurangabad- 431001.
Email: ana@k.st Phone no: +91 9823619992

TABLE OF CONTENTS:

1. Introduction
2. Conditions Requiring Craniotomy
3. Craniotomy
 - 3.1. Definition
 - 3.2. Purpose
 - 3.3. Types of craniotomy
 - 3.4. Goals of craniotomy
4. Procedure For Craniotomy
 - 4.1. Stages of craniotomy
 - 4.1.1.1. Pre Operative Stage
 - 4.1.1.2. Operative Stage
 - 4.1.1.3. Post Operative stage
5. Drugs Associated In Craniotomy
 - 5.1. Analgesics
 - 5.2. Anesthetics
 - 5.3. Dehydrating Agents
 - 5.4. Antibiotics
 - 5.5. Steroids
 - 5.6. Anticonvulsants
6. Case Reports
 - 6.1. Pre operative case report
 - 6.2. Operative case report
 - 6.3. Post operative case report
7. Conclusion
8. Acknowledgment

1. INTRODUCTION:¹

A tumor (also called a neoplasm or lesion) is abnormal tissue that grows by uncontrolled cell division. Normal cells in brain grow in a controlled manner as new cells replace old or damaged cells. For reasons not clearly understood, tumor cells reproduce uncontrollable. Brain tumors are named after the cell type from which they grow. They may be primary (starting in the brain) or secondary (spreading to the brain from another area). Treatment options changes as they

depend on the type of tumor, size and location; whether the tumor has spread; and the age and medical health of the person. Treatment options might be curative and focuses on giving relief from symptoms. More than 120 types of brain tumors can be treated successfully. The new therapies OF surgeries are improving the life span and life quality for many people. Brain surgery has undergone major developments over the past 15 years or so. Result is that neurosurgeons can easily operate many parts of the brain previously thought to be not reachable.

Surgery is the primary treatment for brain tumors that can be removed without causing severe damage. Many benign (non-cancerous) tumors are treated only by surgery. Most malignant (cancerous) tumors, however, require treatment in addition to the surgery, such as radiation therapy and/or chemotherapy.

Craniotomy:^{2,3} The most commonly performed surgery for removal of a brain tumor is called a craniotomy. “Crani” means skull, “otomy” means cutting into. In preparation for a craniotomy, a portion of the scalp is usually shaved, and an incision is made through the skin. Using specialized equipment, a surgeon removes a piece of bone to expose the area of brain over the tumor. The dura mater (the outermost layer of the brain tissue) is opened, the tumor is located and then removed (resected). After the tumor is removed, the bone is usually replaced and the scalp stitched shut.

2. Conditions requiring a craniotomy

Some of the conditions that require craniotomy and surgical repair include:

- Brain cancers
- Infections
- Abscesses
- Cerebral oedema (swelling of the brain)
- Bleeding within the skull.

3. Craniotomy³

3.1 Definition:

A craniotomy is a procedure to remove a lesion in the brain through an opening in the skull (cranium).

3.2 Purpose:

It also may be done to remove a blood clot (hematoma), to control hemorrhage from a weak, leaking blood vessel (cerebral aneurysm), to repair arteriovenous malformations (abnormal connections of

blood vessels), to drain a brain abscess, to relieve pressure inside the brain .A craniotomy may be performed to for a variety of reasons, including, but not limited to, the following:

- diagnosing, removing, or treating brain tumors
- clipping or repairing of an aneurysm
- removing blood or blood clots from a leaking blood vessel
- removing an arteriovenous malformation (AVM) — an abnormal mass of blood vessels (arteries and veins)
- draining a brain abscess — an infected pus-filled pocket
- repairing skull fractures
- repairing a tear in the membrane lining the brain (dura mater)
- relieving pressure within the brain (intracranial pressure) by removing damaged or swollen areas of the brain that may be caused by traumatic injury or stroke
- treating epilepsy — a neurological condition involving the brain that makes people more susceptible to seizures
- implanting stimulator devices to treat movement disorders such as Parkinson's disease or dystonia (a type of movement disorder)

There may be other reasons for your physician to recommend a craniotomy.

3.3 Types of craniotomies:^{4,5}

- Craniectomy
- Endoscopic craniotomy
- "Eyebrow" craniotomy (supra-orbital craniotomy)
- "Keyhole" craniotomy (retro-sigmoid craniotomy)
- Stereotactic craniotomy
- Translabyrinthine craniotomy

An endoscopic craniotomy type of craniotomy involves the insertion of a lighted scope with a camera into the brain through a small incision in the skull.

Craniectomy involves the permanent removal of a portion of the skull. This is done if swelling is likely after brain surgery or if the skull bone flap cannot be replaced for other reasons.

3.4 Goals of craniotomy:³

There are several potential goals of a tumour craniotomy. These may include one or more of the following:

- To establish a diagnosis. This is called a biopsy. This is usually done through a small hole (burr hole), rather than a craniotomy, but in some situations a craniotomy is the best option. Biopsies are often done at the same time as removal of the tumour.
- To reduce pressure on the brain (intracranial pressure). There are several types of surgery to achieve this:
 - Tumour debulking. The goal here is to remove enough of the tumour to reduce the amount of pressure on the brain (partial resection).
 - Tumour removal (excision).
 - Drainage of a cyst (fluid filled structure) associated with the tumour.
- Preventing future problems or deterioration from tumour growth or hemorrhage.
- Curing the condition (benign tumours).
- Increasing the length and quality of survival time (malignant tumours).

4. Procedure Of Craniotomy⁶

4.1 Stages of craniotomy^{6,7}

4.1.1 Pre operative stage:

Test Required Before Surgery:

A number of diagnostic tests are often performed before surgery is recommended or carried out. A brain CT scan is the usual initial investigation that most patients will have had before being referred to a neurosurgeon.

The following investigations may then be ordered:

1. MRI OF Brain

This gives much more detail than a CT scan, and is important for surgical planning. It may also detect smaller tumours and vascular malformations which may be missed with CT.

2. Magnetic resonance spectroscopy (MRS)

MRS gives information about the likely chemical composition of the tumour, and therefore its probable diagnosis. It can be done at the same time as the MRI in some institutions.

3. Positron Emission Tomography (PET) and Single Photon Emission CT (SPECT) scans

These give information about the blood flow and metabolic activity of a mass within the brain. They

are frequently useful in differentiating between a recurrent tumour and the effects of radiotherapy, both of which may look identical on MRI.

4. Cerebral angiography/CT angiogram (CTA)/Magnetic resonance angiogram (MRA)

These tests provide detailed information about the appearance of blood vessels in the brain. Angiography may be helpful where a tumour appears very vascular, or where a diagnosis of a vascular malformation or aneurysm is being considered.

5. CT Chest, Abdomen and Pelvis/Nuclear Medicine Bone Scans/Breast Ultrasound or Mammogram.

These scans help to pick up tumours elsewhere in the body. This process of "staging" is frequently important in deciding the best way to manage brain metastases.

6. Plain X-rays of the skull are rarely needed nowadays.

Neurosurgeon Requires Information before surgery

It is important that you tell your surgeon if you have:

- Blood clotting or bleeding problems
- Ever had blood clots in your legs (DVT or deep venous thrombosis) or lungs (pulmonary emboli), or if anyone else in your family has
- Been taking aspirin, warfarin, or anything else (even some herbal supplements) that might thin your blood
- High blood pressure
- Any allergies or reactions to medications or tapes
- Excessive scarring (keloid) or poor healing after surgery
- Any other health problems

You should tell your anesthetist if you have:

- Heart problems or chest pain
- Respiratory (breathing) problems
- Diabetes
- High blood pressure
- Previous problems with anaesthesia

Your surgeon and/or anesthetist may order several additional tests before surgery, including:

- Blood tests (for anemia, blood clotting problems etc.)
- ECG (to examine your heart electrical activity)
- Chest X-ray

Special precautions:

If you are a smoker it is imperative that you stop 3 or 4 weeks before surgery, and should not resume smoking for at least a few months afterwards (but preferably never!). It is important that you stop certain drugs before surgery, especially ones that thin your blood. If you are taking aspirin, warfarin, or other blood-thinning agents (including herbal products) it is very important that you contact us two weeks before your admission so that we can discuss stopping them with you. If you are taking warfarin we may need to admit you earlier but each case varies, so it is important that you phone and we can discuss the plan for you.

Risk Of Craniotomy:^{7,8}

As with all types of surgery, there is a risk of complications, and the likelihood of these complications will depend upon your condition and exactly what procedure is being undertaken. In general the risks of craniotomy include, but are not limited to:

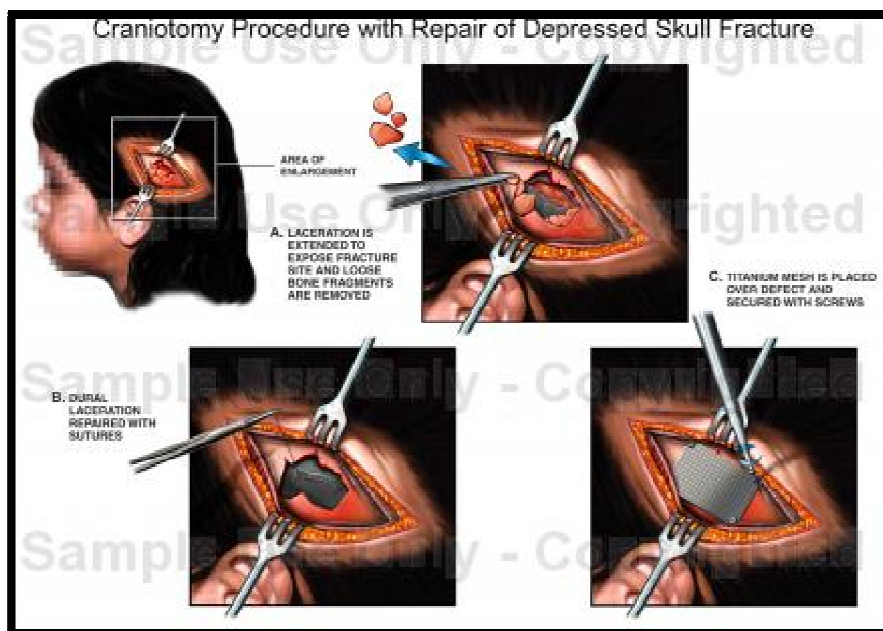
- Stroke or hemorrhage
- Infection
- Seizures
- Impaired speech (dysphasia), with problems either understanding speech or actually speaking
- Blindness
- Deafness
- Memory loss
- Cognitive impairment (problems with your thinking)
- Swallowing impairment
- Balance problems
- Hydrocephalus (fluid build-up within the head necessitating a ventricular drain or shunt)
- Numbness of the skin around the scalp incision
- Headaches (these usually settle after a couple of weeks following surgery, but may last longer)

- Cosmetic issues, with a small dimple in the skull where the holes were drilled.

Risks of anaesthesia:^{16,17}

- Significant scarring ('keloid')
- Wound breakdown
- Drug allergies
- DVT ('economy class syndrome')
- Pulmonary embolism (blood clot in lungs)
- Chest and urinary tract infections
- Pressure injuries to nerves in arms and legs
- Eye or teeth injuries
- Myocardial infarction ('heart attack')
- Stroke
- Loss of life

4.1.2 Operative Stage⁴



Anesthetic and Preparation:

A general anesthetic is given and a breathing ('endo tracheal') tube is inserted. Intravenous antibiotics, and frequently dexamethasone (steroids which reduce some types of brain swelling) and

anticonvulsants (medications to prevent seizures) are administered. A catheter is often placed in the bladder (this will be removed the next day). A dehydrating agent, such as Mannitol, is often given in an attempt to control brain swelling. The patient is then positioned according to the area of the brain that must be operated upon. The hair over the incision area is then clipped and shaved, and the frameless stereotactic navigation system is set up. Local anesthetic and adrenaline are then injected into the proposed incision site.

Incision Closure:

A curved or straight incision is made in the scalp over the appropriate location. The scalp flap is then pulled back to expose the skull.

Craniotomy (bone removal):¹

One or more small holes (burr holes) are drilled in the skull with a high speed drill. This sounds dangerous but is actually quite safe in skilled hands. A surgical saw (craniotome) is then used to connect the burr holes and create a "window" in the skull through which brain surgery will take place. The removed piece of bone (bone flap) is kept sterile, and is usually secured back in position at the end of the operation. When the dura (lining over the brain) is exposed, an assessment of the likely location of the underlying tumour is performed. The dura is then incised with a scalpel and scissors, and the underlying brain is exposed. A small incision is made in the surface of the brain and the neurosurgeon proceeds along the appropriate path until the tumour is reached. After the tumour is identified, it is carefully dissected from the normal surrounding brain.

A biopsy (small piece of the tumour) is sent to the pathologist for analysis. A 'frozen section' analysis usually takes around 20-30 minutes and should tell the surgeon whether the tissue taken is likely to be a tumour, and roughly what type of tumour it is. The frozen section is not, however, 100% accurate, and the tissue is then prepared and stained for a more thorough and accurate pathological evaluation, a process which usually takes 2-3 days.

Special microsurgical and other instruments are used by the neurosurgeon to locate, incise, and remove the tumour. These may include a microscope or special magnification glasses ('loupes'), lasers, and an ultrasonic tissue aspirator (abbreviated to 'CUSA') that breaks up and then aspirates (sucks away) the abnormal tissue. With meningiomas and metastatic tumours, it is usually easy to distinguish the tumour

from the normal brain tissue around them, and a fairly complete excision is usually possible (also known as a 'gross macroscopic excision'). This is in contrast to surgery for gliomas, where the tumour boundaries are usually unclear and difficult to identify. Furthermore, the tumour cells in glioma usually spread well beyond the visible edges of the tumour, deep into the brain and sometimes into the other side of the brain. Once the tumour has been removed, the surgeon ensures that there is no significant bleeding (this process is known as obtaining haemostasis). In situations where there is a large cystic component to the tumour, a drain and reservoir may be inserted into the cystic cavity. This allows easy drainage of fluid if it accumulates in the cyst after surgery, by simply passing a small needle through the scalp and into the reservoir. An intracranial pressure monitoring device is occasionally implanted, and a drain is sometimes placed within the fluid channels in the middle of the brain (the ventricles).

Bone Replacement:

After the dura has been stitched back together, the piece of bone that was removed is replaced and secured using small plates and screws, or several small clamps which hold the bone flap fairly firmly. If there are significant defects in the skull from the drilled holes (which may cause cosmetic issues or may feel uncomfortable when combing your hair) these will be filled and the skull recontoured using acrylic or titanium. This is known as a reconstructive cranioplasty.

Incision closure:

The operation is completed when the incision is closed, usually in two or three layers. Unless dissolving suture material is used, the skin staples will have to be removed after the incision has partially healed (usually around 7 days after surgery). Before surgery the patient may be given medication to ease anxiety and to decrease the risk seizures, swelling, and infection after surgery. Blood thinners (Coumadin, heparin and aspirin) and non steroidal anti-inflammatory drugs (ibuprofen, Motrin, Advil, aspirin, Naprosyn, Daypro) have been correlated with an increase in blood clot formation after surgery. These medications must be discontinued at least seven days before the surgery to reverse any blood thinning effects. Additionally, the surgeon will order routine or special laboratory tests as needed. The patient should not eat or drink after midnight the day of surgery. The patient's scalp is shaved in the operating room just before the surgery.

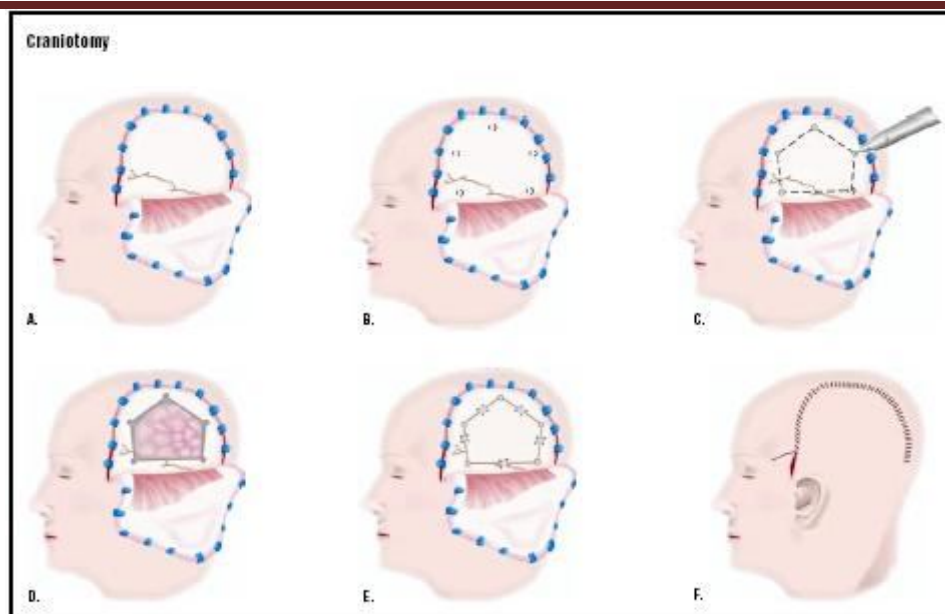


Fig.1: Procedure for craniotomy: In a craniotomy, the skin over a part of the skull is cut and back (A). Small holes are drilled into the skull (B), and a special saw is used to cut the bone between the holes (C). The bone is removed, and a tumor or other defect is visualized and repaired (D). The bone is replaced (E), and the skin closed (F).

4.1.3 Post Operative Stage⁸

Medication

Medications are used to control some of the common side effects of brain tumors.

- Corticosteroid medications, such as dexamethasone (Decadron), are prescribed to reduce swelling and inflammation around the tumor. Because steroid medications can cause stomach ulcers and gastric reflux, famotidine (Pepcid) or pantoprazole (Protonix) are prescribed to reduce the amount of acid produced in the stomach.
- Furosemide (Lasix) or mannitol (Osmitrol) may be used to control edema and intracranial pressure.
- Anticonvulsant medications are used to prevent or control seizures. The most common ones include phenytoin (Dilantin), valproic acid (Depakote), carbamazepine (Tegretol),

Neurological Observation:

Craniotomy is a major surgical procedure performed under general anesthesia. Immediately after surgery, the patient's pupil reactions are tested, mental status is assessed after anesthesia, and movement of the limbs (arms/legs) is evaluated. Shortly after surgery, breathing exercises are started to clear the lungs. Typically, after surgery patients are given medications to control pain, swelling, and seizures. Codeine may be prescribed to relieve headache. Special leg stockings are used to prevent blood clot formation after surgery. Patients can usually get out of bed in about a day after surgery and usually are hospitalized for five to 14 days after surgery. The bandages on the skull are removed and replaced regularly. The sutures closing the scalp are removed by the surgeon, but the soft wires used to reattach the portion of the skull that was removed are permanent and require no further attention. Patients should keep the scalp dry until the sutures are removed.

Post operative pain and nausea:

A dull headache is common, but is usually all the post-operative pain that is expected. Pain medication will be ordered for this. Nausea and vomiting may also occur, and these will be treated with medications.

Incision care:

The incision will be covered with a dressing, and sometimes a crepe bandage. The wound is usually checked, cleaned and redressed 3 or 4 days after surgery. The staples are usually removed 7 or 8 days after surgery. The wound must be kept dry for the first 2 weeks following your operation.

Fluid Replacement and Nutrition:

Intravenous fluids will be ordered during the early recovery period and continued until you are fully awake and tolerating a reasonable amount of liquid by mouth. For the first few days, all fluids intake and output will be carefully monitored, due to the danger of brain swelling lessens.

Emotional changes:

Brain surgery is generally fairly stressful, both physically and psychologically. It is common to feel discouraged and tired for several days after surgery. This emotional let-down must not be permitted to obstruct the positive attitude essential to recovery and a return to fairly normal activity.

Discharge:

The amount of time spent in the hospital may be different for each patient, and will depend upon the condition for which you underwent a craniotomy, as well as your post-operative recovery. Discharge is planned in consultation with the patient, their family, as well as the physiotherapist, occupational therapist, nursing staff, and neurosurgeon. Some patients are able to be discharged home, but others require a period of inpatient rehabilitation to optimize their outcome and make it as safe as possible for them to return home.

5. Drugs Associated In Craniotomy^{9,10,11}

Sr.No	Drug Associated In Craniotomy	Examples
01	Analgesic	Morphine ,Codine
02	Anesthetic	Propofol, Fentanyl
03	Dehydrating Agent	Mannitol
04	Antibiotic	Oxacillin ,Cefuroxime
05	Steroid	Dexamethasone
06	Anticonvulsant	Phenytoin, Valproic Acid

5.1 Analgesics:^{11,13}

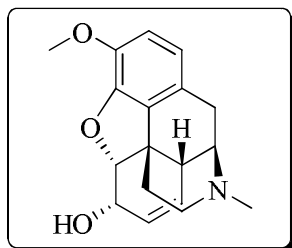
Certain analgesics are used to relieve the pain after the procedure given as

1. Morphine
2. Meperidene
3. Codien
4. Ketorole
5. Acetaminophen

Codien

Codeine is an opioid analgesic.

Moa: Opioids produce analgesia through their agonist effects on opiate receptors in the central nervous system. Codeine is metabolized in the liver to its active form, morphine.[11] Some individuals receive little or no analgesic effects from codeine due to a genetic inability to metabolize it or from interactions with other medications.



Dose: codeine 15-60 mg every 4-6 hours.

Use: Analgesic

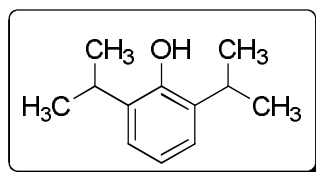
Anesthetics

1. Propofol
2. Dexmedetomidine in combination with nitrous oxide and sevoflurane
3. Fentanyl or remifentanyl

Propofol:

It is an anesthetic agent; Similar in properties to thiopental anesthetic of choice for ambulatory surgery in outpatients.

MOA: The action of propofol involves a positive modulation of the inhibitory function of the neurotransmitter gamma-aminobutyric acid (GABA) through GABAA receptors.



Use: Anesthetic agent

6. Case Reports:^{13,16,17}

6.1 Case Report (pre_operative_case)

A 38-yr-old man was scheduled for resection of a left temporal brain neoplasm. The patient presented with a 14-month history of increasing difficulty expressing himself and poorly controlled partial complex seizures. His medical history was otherwise unremarkable. The patient received no preoperative medication. In the operating room the patient was monitored with a noninvasive blood pressure cuff, a pulse oximeter, and electro cardiogram. The approximate level of sedation was measured by using a Bispectral electroencephalogram index (BIS). Anesthesia^{18,19} was induced with propofol 200 mg and fentanyl 100mg IV. A laryngeal mask airway (LMA) was then placed. A right radial arterial line and Foley catheter were inserted after induction of anesthesia. The scalp nerves were blocked with 0.5% bupivacaine (4). The patient was then positioned in the right decubitus position. Anesthesia was maintained with 70% nitrous oxide, dexmedetomidine infusion (initial dose 1 mg/kg IV over 30 min followed by continuous infusion of 0.4 mg · kg⁻¹ · hr⁻¹ IV), and sevoflurane (0.3%–0.7%).neoplasm. Sevoflurane concentration was adjusted to maintain a BIS index between 50 and 60. We observed a decrease in heart rate from 62–78 bpm to 50–60 bpm and blood pressure from 95–110/55–65 mm Hg to 90–100/52–60 mm Hg after an initial dose of dexmedetomidine. The patient was breathing spontaneously throughout the procedure. Skin incision, bone flap removal, and dissection of dura were uneventful. Twenty minutes before the intended awakening, ondansetron 4 mg IV was administered, sevofluranewas discontinued and dexmedetomidine infusion was reduced to 0.2 mg · kg⁻¹ · hr⁻¹. The LMA was removed, and oxygen was administered via nasal cannula. Vital signs remained stable. At a dexmedetomidine infusion rate of 0.2 mg · kg⁻¹ · hr⁻¹the patient was arousable, but too sedated to complete counting or sentence completion tasks (BIS 75–80). The infusionrate was reduced to 0.1 mg · kg⁻¹ · hr⁻¹. BIS increased to 95 within 15 min. Over 2 h were spent performing language localization. In addition to dexmedetomidine, the patient received fentanyl 100 mg. The tumor adjacent to thelanguage areas was dissected from the normal brain while the patient was undergoing continual testing to assess languages the resection progressed. The BIS was approximately95 while the patient was awake. An arterial blood gas sample taken during this time revealed a carbon dioxidepartial pressure (Paco₂) of 42 mm Hg and oxygen partial pressure (Pao₂) of 156 mm Hg. The remainder of the surgical procedure was uneventful. The patient was sedated with propofol 150 mg IV and aLMA was reinserted. Dexmedetomidine infusion was discontinued and anesthesia was maintained with nitrous oxide and sevoflurane. On completion of the procedure, sevoflurane and nitrous oxide were stopped. The patient was responsive to verbal commands

immediately after the LMA removal. He remembered that he was awake during the tumor resection, but could not recall any details.

6.2 Case Report (operative case)¹⁵

Psychotic manifestations in brain tumour patients: 2 case reports from South Africa

JR Ouma .University of the Witwatersrand, Department of Neurosurgery, Johannesburg Hospital^{15,16}

Abstract

Two cases are presented of adult males diagnosed with psychosis who were found to have intraventricular tumours (central neurocytomas). In both cases the psychotic manifestations disappeared following surgical removal of the tumours. The relationship between structural brain lesions and psychotic manifestations is discussed. Brain tumour patients usually manifest with features of raised intracranial pressure, focal neurological deficits and seizures. Psychotic manifestations are not usually seen. It must be recognized however that though rare, these can be the presenting features of intracranial tumours. Patients presenting with psychosis associated with atypical manifestations such as advanced age, resistance to treatment or focal neurological deficits and papillo-oedema should warrant a full workup to exclude structural intra-cranial mass lesions. The main objective of this report is to highlight this population of patients who can be helped if properly diagnosed..

2.1. Case A

A 26-year-old black African male was admitted to the Johannesburg Hospital with an eight-month history of auditory hallucinations (mainly of command), delusions of grandeur and non Spurposeful violent outbursts with no clouding of consciousness. He complained of headaches occasionally. He had had no prior history of psychosis. There was no history of substance abuse, febrile illness or any other significant medical complaints. He was placed on anti-psychotic medication by the psychiatric service but consistently defaulted on his treatment so that he was eventually admitted to the medical floor and a CT scan obtained on the basis of concern about the reported headaches. Prior to this, he had not been formally investigated. Clinically he was in good general condition. He had bilateral papillo-oedema and no other focal neurological deficits, and was fully conscious. Testing of mental status revealed disturbances in memory and higher cognitive functions especially calculations and proverb interpretation. The remainder of the parameters were within the normal limits.

A CT scan of the brain (fig2) showed a homogeneously enhancing mass lesion in the left lateral ventricle associated with ventriculomegaly of that ventricle mass effect and midline shift.

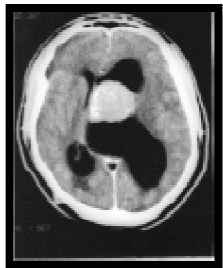


Fig.2.CT Scan of brain

He underwent a craniotomy at which the tumour was approached via the corpus callosum. It was pinkish-grey, moderately vascular and soft in nature. It was completely removed and histological examination showed it to be a central neurocytoma. There was immediate resolution of all his psychotic symptoms following the operation.

6.3 Case B

A 43-year-old black African male presented with a 1½-year history of being extremely psychotic characterized by non-specific auditory hallucinations, persecutory delusions and episodes of non-directed violence. Unfortunately there was no family available to give history regarding substance abuse or any significant past medical events. He had been committed to a psychiatric institution in Johannesburg where the control of his condition was difficult even on multi-drug therapy. There was no record of any previous investigations having been done specifically with regard to his psychosis, nor any details regarding the treatment he had been on prior to admission to the psychiatric hospital.

On the basis of this difficulty in treatment, a CT scan of the brain was obtained ([Figure2](#)). Clinically, he tended to be aggressive and uncooperative. He had no focal neurological signs.

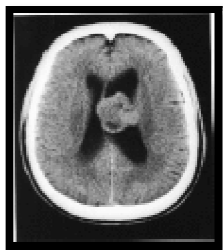

Fig.3.CT Scan of brain

It was not possible to obtain formal mental status or neuropsychological testing owing to his state. There was no papillo-oedema on fundoscopy. The CT scan demonstrated a predominantly solid enhancing mass in the left lateral ventricle and attached to the septum pellucidum. There were multiple

cystic areas in the lesion. In addition, there was moderate hydrocephalus of both lateral ventricles. He too underwent a craniotomy with approach through the corpus callosum and complete removal of the tumour, which, as in the previous case, was also demonstrated to be a central neurocytoma. Post-operatively, he was aphasic and had a right hemi paresis. These deficits improved to total recovery over a period of two weeks at which point he was found to have no residual psychotic manifestations.

Conclusion

A craniotomy is an operation to open the skull (cranium) in order to access the brain for surgical repair. Conditions that require craniotomy and surgical repair include brain cancers, infections, abscesses, cerebral oedema (swelling of the brain) and bleeding within the skull. There are many different types of brain surgery, but the recovery process following craniotomy is much the same. Recovery depends on many factors, including the type and severity of brain injury, the type of surgery and whether or not there were neurological deficits before surgery. In this article various case studies have been discussed showing different types of lesions and tumor removal methods.

ACKNOWLEDGMENT

The authors express their deepest gratitude to Mrs. Fatima Rafiq Zakaria for her moral support and Dr. M.H. Dehghan, Principal for providing the facilities.

REFERENCES:

1. The essential guide to brain tumors. National Brain Tumor Society website. Available at: <http://www.braintumor.org/patients-family-friends/about-brain-tumors>
2. Guide to the care of the patient with craniotomy post-brain tumor resection. American Association of Neurological Nurses website. Available at: <https://www.aann.org/pdf/cpg/aanncraniotomy.pdf>. Accessed February 6, 2013.
3. White-Guthro M. Craniotomy. EBSCO Nursing Reference Center website. Available at: <http://www.ebscohost.com/dynamed/>. Updated February 24, 2012. Accessed February 6, 2013.
4. Central Brain Tumor Registry of the United States (CBTRUS). Fact Sheet. 2011. Accessed at www.cbtrus.org/factsheet/factsheet.html on October 31, 2011.

5. Central Brain Tumor Registry of the United States (CBTRUS). CBTRUS Statistical Report: Primary Brain and Central Nervous System Tumors Diagnosed in the United States in 2004-2007. Central Brain Tumor Registry of the United States; 2011. Accessed at www.cbtrus.org/2011-NPCR-SEER/WEB-0407-Report-3-3-2011.pdf on November 8, 2011.
6. Connolly, E. Sanders, ed. *Fundamentals of Operative Techniques in Neurosurgery*. New York: Thieme Medical Publishers, 2002.
7. Gebel, J. M., and W. J. Powers. "Emergency Craniotomy for Intracerebral Hemorrhage: When Doesn't It Help and Does It Ever Help?" *Neurology* 58 (May 14, 2002): 1325-1326.
8. Clatterbuck R, Tamargo R. Surgical Positioning and Exposures for Cranial Procedures. In: Winn H, editor. *Youmans Neurological Surgery*. 5 ed. Philadelphia, Pennsylvania: Saunders Elsevier Inc; 2004. pp. 623–645.
9. Goodkin R, Mesiwala A. General Principles of Operative Positioning. In: Winn HR, editor. *Youmans Neurological Surgery*. 5th ed. Saunders: Elsevier Inc.; 2004. pp. 595–621.
10. http://www.thebarrow.org/Neurological_Services/Brain_Tumor_Center/Hypothalamic_Hamartomas/203780.
11. Lamszus K. Meningioma pathology, genetics, and biology. *J Neuropathol Exp Neurol*. 2004; 63:275-286.
12. Todd MM, Warner DS, Sokoll MD, et al. A prospective comparative trial of three anesthetics for supratentorial craniotomy: fentanyl/propofol, isoflurane/N₂O, and fentanyl/N₂O. *Anesthesiology* 1993;78:1005–20.
13. Adams RW, Cucchiara RF, Gronert GA, et al. Isoflurane and cerebrospinal fluid pressure in neurosurgical patients. *Anesthesiology* 1981;54:97–9.
14. Feldman Z, Kanter MJ, Robertson CS, et al. Effect of head elevation on intracranial pressure, cerebral perfusion pressure, and cerebral blood flow in head-injured patients. *J Neurosurg* 1992;76:207–11.
15. JR Ouma Psychotic manifestations in brain tumour patients: 2 case reports from South Africa ,*African Health Sciences*. 2004 December; 4(3): 190–194.
16. Sato T, Takeichi M, Abe M, Tabuchi K, Hara T. Frontal lobe tumour associated with late-onset seizure and psychosis: a case report. *Jpn J Psychiatry Neurol*. 1993 Sep;47(3):541–544.
[PubMed]

17. Mordecai D, Shaw RJ, Fischer PG, Mittelstadt PA, Cuterman T, Donaldson SS. Case study: suprasellar germinoma presenting with psychotic and obsessive-compulsive symptoms. *J Am Acad Child Adolesc Psychiatry*. 2000 Jan;39(1):116–119. [PubMed]
18. Berkenstadt H, Ram Z. Monitored Anaesthesia Care in awake craniotomy for brain tumour surgery. *Isr Med Assoc J* 2001;3:297-0
19. Blanshard HJ, Chung F, Manninen PH. Awake craniotomy for removal of intracranial tumour: consideration of early discharge. *Anesth Analg* 2001;92:89-4.